

Original article:

Delayed presentation of hemothorax after 14 days of chest trauma

Sangram Karandikar , Tanveer Parvez Shaikh , Sharique Ansari , Nisha Mandhane , Sandesh Deolekar

Department of Surgery, DY Patil School of Medicine, Nerul, Navi Mumbai, India

Corresponding author: Dr Sangram Karandikar

Abstract

Intrathoracic bleeding may occur following blunt chest trauma, and can be classified as minimal, moderate or massive, according to the amount of blood present. The diagnosis of hemothorax is established by clinical examination, plain chest radiograph or, more recently, by ultrasound of the chest. Computed tomography of the chest helps to define the nature of the chest injury but is not indicated in all patients because of lack of availability, radiation dose and expense. Significant intrathoracic bleeding following chest trauma going unrecognized for more than 2–3 days is highly unusual. Here we present a trauma patient with massive hemothorax 14 days post blunt trauma to chest due to bike handle.

Keywords : Hemothorax, blunt chest trauma, delayed massive hemothorax, rib fracture

Introduction

Hemothorax post trauma usually presents immediately but delayed presentation of hemothorax is a rare presentation. Any patient coming to casualty with blunt chest trauma should be admitted and observed for a day or two especially if there is a fracture of the ribs. Patient should be advised to visit the hospital in a week for reevaluation or if there are any signs of breathing difficulty or pain in chest. Not all blunt traumas can lead to hemothorax but patients with rib fractures are more prone to develop hemothorax.

Case history

A 26-year-old man presented with left-sided chest pain after a blunt trauma to chest from bike handle. Physical examination detected tenderness over the left lower posterolateral chest wall. The initial chest x-ray demonstrated fractures of the left eighth rib

with no evidence of hemothorax. The hemoglobin recorded was 13.9 g/dl. Patient did not have breathlessness and was maintaining oxygen saturation at 100% on room air. The patient was admitted for 24 hours observation and was discharged the next day following a repeat chest x-ray which showed no change. Fourteen days later the patient presented with increasing chest pain and tachycardia. X-ray chest was done which showed near total opacification of the left hemothorax (Figure 1) with collapsed lung and fracture of the 8th rib. Decision was taken to insert 24 FG Intercostal Drainage tube (ICD). ICD produced an intermittent drainage of altered blood @ 300 cc/hr over 4 hours. Hemoglobin was 10.7 g/dl. The chest tube continued to drain diminishing amounts of altered blood for next 24 hours. The output then ceased and repeat chest x ray still showed no expansion of the

ipsilateral lung. So, assuming blockage of the ICD tube, it was replaced with a new ICD tube which drained only 150 cc over next 12 hrs with x-ray showing no expansion of lung. Computed tomography (CT) of the chest and abdomen confirmed a massive collection in the left pleural cavity and left lung collapse (Figure 2). There were no abdominal injuries identified. The patient's pulmonary status did not return to baseline despite analgesia, respiratory exercise and incentive spirometry. A follow-up chest CT showed high-density fluid within the left pleural sac consistent with residual hemothorax, collapse of the posterior basal segment of the lower lobe of the left lung, and multiple atelectatic bands restricting the left lung expansion. Thoracotomy was performed to free the entrapped lung and evacuate the hematoma in pleural space. The patient improved rapidly following the procedure and was discharged one week later.

Discussion

Intrathoracic bleeding may occur following blunt chest trauma, and can be classified as minimal, moderate or massive, according to the amount of blood present. The diagnosis of hemothorax is established by clinical examination, plain chest radiograph or, more recently, by ultrasound of the chest¹. Hemothorax occurring after hospital discharge can be dangerous due to respiratory distress. It is the result of any of several chest injuries, including uncomplicated and complicated rib fractures, injuries to the diaphragm, sternal fractures, and rupture of the thoracic aorta, which may go unrecognized. Some cases of hemothorax are serious and life-threatening while others create symptoms without long term consequences. Other cases may be picked up in an asymptomatic patient, especially when routine thoracic CT scanning is performed according to

protocol². Simon et al. described twelve cases that presented with delayed hemothorax 18 hours to six days after severe blunt chest trauma associated with rib fractures³. The authors characterized delayed hemothorax as a potentially lethal complication unique to displaced rib fractures following blunt chest trauma. It is clear from the literature that fatal consequences of chest trauma are not all immediate⁴. Sharma et al. reported an incidence of 5% for delayed hemothorax, defined as hemothorax occurring after discharge from the hospital⁵. These patients were found to be less severely injured, and initially were observed for shorter periods in the hospital. Rib fractures were present in 75% of cases. In 2006, Chilma et al. reported delayed massive post-traumatic hemothorax in a patient without rib fractures⁶. At operation, it was found that the site of hemorrhage was the internal mammary artery. The patient reported here presented after a relatively minor injury mechanism (fall at home), and the diagnosis of rib fractures was established at the time of initial presentation. There were no clinical findings to suggest the catastrophic hemorrhage which followed. Upon return, the patient did not present in shock, which is consistent with sustained slow blood loss with compensation. The patient, however, had significant respiratory distress. These findings are consistent with those of other authors^{3,6}. Nonetheless, volume resuscitation is the initial therapy followed by tube thoracostomy to evacuate the hematoma from the pleural space. Close monitoring of the chest tube output is essential to exclude ongoing hemorrhage. The failure of tube thoracostomy to completely evacuate the collection in pleural space and allow lung re-expansion in this patient was not unexpected. After 14 days of slow intrapleural bleeding, clotting, even early clot organization and adhesions were

anticipated. It can be debated whether minimally invasive thoracoscopy could have been employed earlier, but the patient initially improved. Thus, similar chest trauma management principles should apply whether rib fractures with associated hemothorax are recognized early on during a patient's initial presentation or at a later date. Most of these cases need close observation, repeated physical examination, and hospitalization. Hemothorax complicating blunt chest trauma is treated with a chest tube as it was in this cases. Thoracotomy is rarely needed unless the massive hemothorax causes hemodynamic instability or the tube thoracostomy is ineffective, for example, in the presence of organized

hemothorax, empyema, or persistent collapsed lung. Minimally invasive techniques offer an attractive alternative to thoracotomy in the stable patient.

Conclusion

Delayed bleeding following blunt chest trauma is uncommon but can be massive, affecting pulmonary function and hemodynamic status. In this report, a patient presented with a massive hemothorax 14 days post-injury. The duration of intra-pleural retained blood clots reduces the likelihood of successful management by tube thoracostomy alone. Early follow-up CT can define the ineffectiveness of tube thoracostomy and lead to early use of therapeutic minimally invasive thoracoscopy

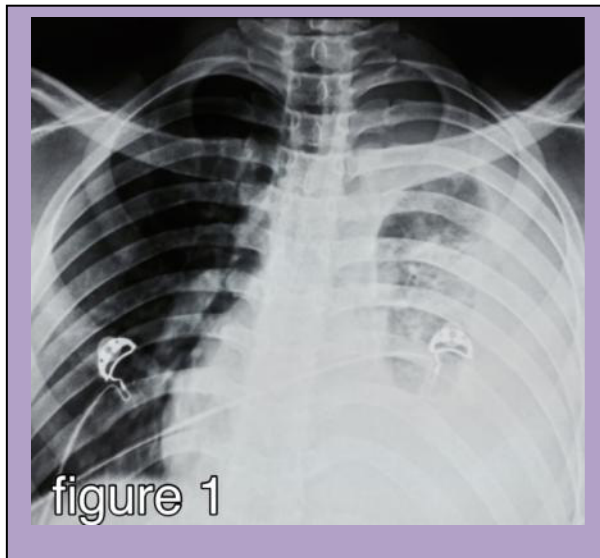


Figure 1 X ray chest showing left hemothorax

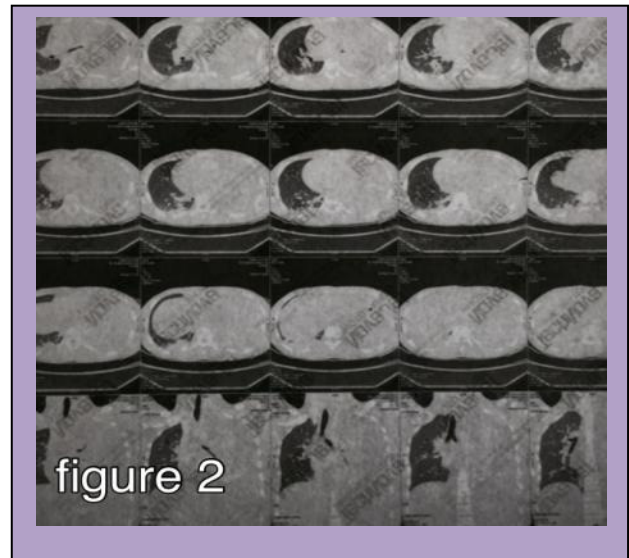


Figure 2 CT scan showing left lung collapse

References

1. Dente C.J., Ustin J., Feliciano D.V., Rozycki G.S. et al. Accuracy of thoracic ultrasound for detection of pneumothorax is not sustained over time: a preliminary study. *J Trauma*. 2007; 62:1384–1389.
2. Deunk J., Dekker H.M., Brink M., van Vugt R., Edwards M.J. and van Vugt A.B. Value of indicated computed tomography scan of the chest and abdomen in addition to conventional radiologic work-up for blunt trauma patients. *J Trauma*. 2007; 63:757–763.

3. Simon B.J., Chu Q., Emhoff T.A., Fiallo V.M. and Lee K.F. Delayed hemothorax after blunt thoracic trauma: an uncommon entity with significant morbidity. *J Trauma*. 1998; 45:673–676.
4. Rodriguez A. and Elliot D. Blunt rupture of the thoracic aorta. *Advances in Trauma and Critical Care*. 1993; 8:145–181.
5. Sharma O.P., Hagler S. and Oswanski M.F. Prevalence of delayed hemothorax in blunt thoracic trauma. *Am Surg*. 2005; 71:481–486.
6. Chinnan N.K., Shabaan A.I. and Palkar S.D. Delayed life-threatening hemothorax without rib fractures after blunt trauma. *Indian J Crit Care Med*. 2006; 10:254–256.
7. Khoschnau, Sherwan R., Mazin AM Tuma, and Kimball Maull. "Delayed post-traumatic hemothorax." *Journal of Emergency Medicine, Trauma and Acute Care* 2012 (2012).